

# A decade with silicone hydrogels: Part 2

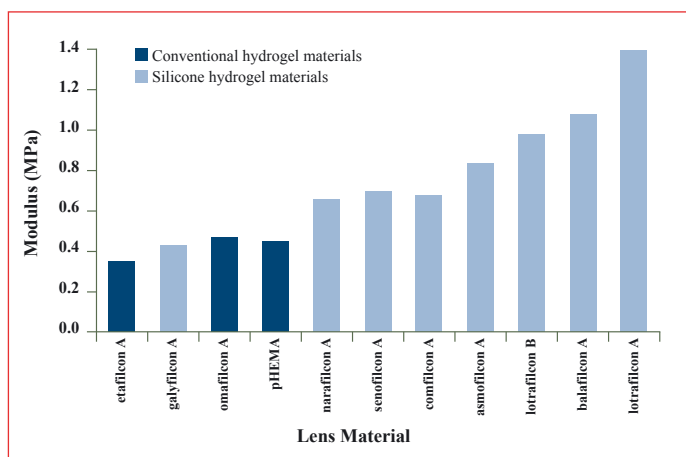
Dr Karen French & Professor Lyndon Jones

In the first article of this series of two we discussed several aspects of the clinical performance of silicone hydrogel (SiH) materials and currently available lenses. In addition to looking at the oxygen performance, the evidence for potentially reduced symptoms of discomfort and end of day dryness with SiHs was examined. In this second article, we will look at additional aspects of SiH material and surface properties, as well as discussing the most recently published information on the incidence of inflammatory and infective complications and commenting on potential future developments for SiH contact lens materials.

## Mechanical properties

In general, SiH materials will have a higher modulus of elasticity than the majority of conventional hydrogel materials (Figure 1).<sup>1-4</sup> This means that the material is ‘stiffer’ and may behave clinically differently to conventional HEMA-based

**Figure 1: Elastic modulus of a range of silicone hydrogel and conventional hydrogel materials\***



\*Values stated are manufacturers’ stated values and have been obtained using non-standardised methods.

hydrogel materials. The first commercial SiH materials contained high relative amounts of silicone to achieve the desired aim of high oxygen permeability,<sup>1-4</sup> as these initial materials were primarily intended for overnight wear. This high siloxane content resulted in materials that were substantially higher in elastic modulus than HEMA-based materials.

Increased modulus makes materials easier to handle and potentially more durable.<sup>5-7</sup> However, accurate fitting of the lens becomes slightly more critical than with conventional soft lens materials.<sup>2, 6, 8-10</sup> A flat fitting, stiff lens does not drape as well over the cornea and can result in the lens edge sitting away from the cornea, producing so-called “edge-fluting” and subsequent reduced comfort.<sup>2, 10, 11</sup> Following the initial launch of lotrafilcon A in a single base curve, a second steeper base curve was introduced to allow a wider range of patients to be optimally fitted. In a study carried out by Dumbleton and colleagues,<sup>7</sup> 23% of patients needed the steeper base curve to achieve a comfortable fit and many SiH lenses now have more than one base curve to choose from. As a result of the increased modulus of SiH lenses, clinical performance and comfort is often enhanced with SiH materials if the steeper base curve option is initially chosen when there is a choice of base curves.<sup>10</sup> In addition to a compromise in initial comfort, there are several clinical complications that can arise as a result of mechanical irritation from a non-optimal fitting, stiff lens material.<sup>2, 11-14</sup> These include superior epithelial arcuate lesions (SEALs), contact lens related papillary conjunctivitis (CLPC) and mucin ball production.<sup>11-23</sup> These are particularly an issue in a continuous wear (CW) modality. It is noticeable that the incidence of such mechanical complications has been reduced by the introduction of newer SiH materials with lower moduli,

an increase in base curve options and also changes in the back surface design, including changes to the so-called “first generation” lenses.

### Superior Epithelial Arcuate Lesions (SEALs)

SEALs appear as thin arcuate lesions in the superior cornea between approximately 10 and 2 o'clock.<sup>15, 24-27</sup> They are usually located within 1 to 3 mm of the superior cornea in the area that would usually be covered by the upper lid (*Figure 2*). They are best highlighted by staining with fluorescein and can appear up to 0.5mm wide and 2 to 5mm in length, often with poorly defined edges. They may be bilateral and are often asymptomatic.<sup>24, 25, 28</sup> If questioned specifically, the patient may report a mild foreign body sensation or some discomfort, irritation or edge awareness. There is rarely any underlying inflammation, although very occasionally the practitioner may note some injection of limbal vessels or underlying diffuse infiltrates. The depth of the lesion can be anything from superficial arcuate staining to the full epithelial depth or an epithelial ‘split’.

**Figure 2: Superior Arcuate Epithelial Lesion (SEAL) induced by wearing a silicone hydrogel lens with a high modulus**

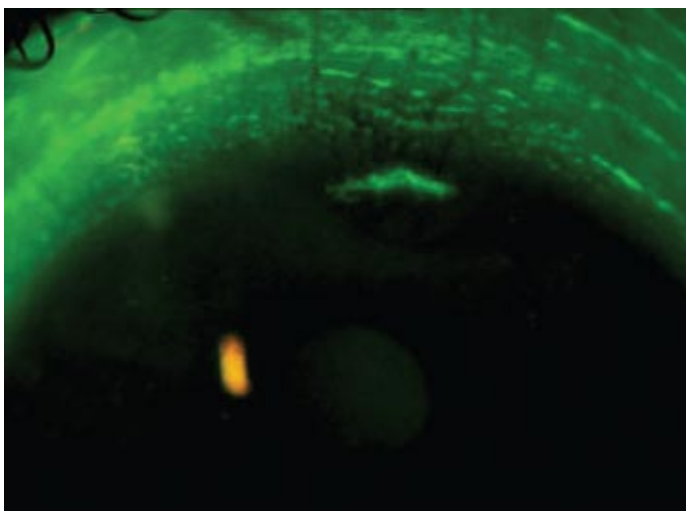


Image courtesy of Simone Schneider, Centre for Contact Lens Research, University of Waterloo, Canada.

The incidence of SEALs with conventional hydrogels is low. However, the introduction of SiH lenses has led to an increase in the number of reports of SEALs, particularly when the lens is worn on a CW basis.<sup>12-16, 27, 29</sup> Varying estimates from 0 to 5% of eyes present at aftercare with SEALs, the majority of these being of a relatively low grade.<sup>30</sup> In a specific study looking at the incidence of SEALs with a first generation SiH lens, up to 4.5% of eyes per year of lens wear were reported to have experienced SEALs with CW.<sup>13</sup>

Several theories have been put forward as to the aetiology of SEALs.<sup>12, 13, 15, 24, 31</sup> These include mechanical pressure or tear film thinning in the superior limbal area as a result of pressure from the upper eyelid and the lens edge; hypoxia as a result of the thicker lens edge; and epithelial desiccation. The increasing incidence of SEALs with the use of higher modulus SiH materials certainly supports a mechanical aetiology, although it is likely that there are other contributing factors in certain patients. Clinically, it is felt that SEALs occur less frequently with lower modulus SiH materials and that the incidence of SEALs is now reduced compared with that seen with the initially released SiH materials.

### Contact lens related papillary conjunctivitis (CLPC)

This is a familiar condition that primarily affects the upper tarsal conjunctiva and has a multifactorial aetiology. It is described as an allergy-like reaction, especially to protein deposition on the lens surface, but mechanical trauma has also been indicated as a causative factor.<sup>32-36</sup> With the first generation SiH lenses it would appear that increased mechanical irritation of the palpebral lid surface due to a higher modulus material, as well as surface wettability changes and edge effects, may be responsible for a higher incidence of CLPC.<sup>12, 13, 17, 19, 37, 38</sup>

Symptoms of CLPC include discomfort, or foreign body sensation, and itching. There may be an increased production of mucus, especially first thing in the morning, and the vision may be variable as a result of the mucus smearing across the front surface of the lens. In more advanced stages, vision can become variable as a result of excessive lens movement on blinking. The symptoms of mechanically mediated CLPC may have a more rapid onset than an immune-mediated response.<sup>13</sup>

**Figure 3: Localised Contact Lens Associated Papillary Conjunctivitis (CLPC) following continuous wear of a high modulus, silicone hydrogel lens**

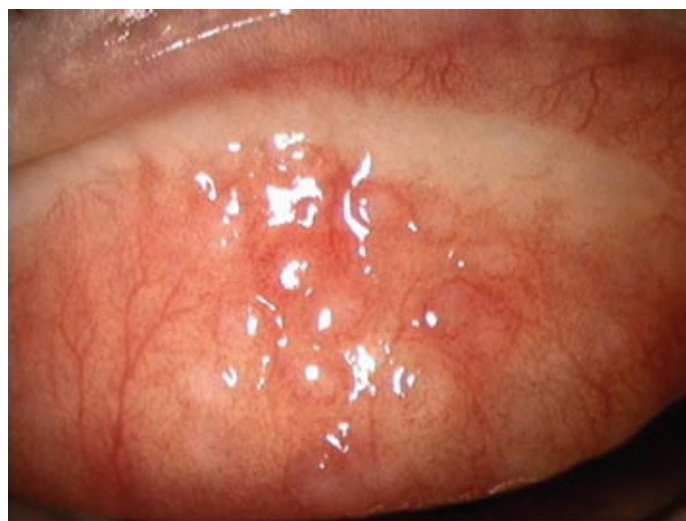

Image courtesy of Brian Tompkins, Private Practitioner, Northampton, UK.

The signs of CLPC can only be observed when the upper lid is everted. There is increased roughness of the upper tarsal conjunctiva and hyperaemia. The papillary response and associated hyperaemia is variable and may be diffuse or localised (*Figure 3*).

CLPC is reported to occur more frequently with SiH CW. Incidence rates of between 3 and 7% of eyes per year of lens wear are reported for first generation SiH lenses worn on a CW basis,<sup>13, 17, 39, 40</sup> although lower rates have been indicated by more recent studies involving steeper base curve lenses and more recent SiHs with lower moduli.<sup>13</sup> Localised responses confined to a small central region near the lid margin are more frequently reported with SiH wear than that seen with polyHEMA-based wear.<sup>17, 19</sup>

Most of the CLPC cases in SiH lens wearers are considered to be mechanical in nature and consequently the condition resolves quickly upon cessation of lens wear.<sup>12, 13</sup> When the condition has subsided, lens wear may be resumed but a change in lens wearing patterns such as moving from CW to daily wear (DW) or a change in lens to a lower modulus material may be appropriate.

### Post lens debris (Mucin balls)

Mucin balls can be occasionally seen in more than 50 percent of patients who wear SiH lenses on a CW basis,<sup>20</sup> although they can also be seen in smaller numbers when these lenses are worn on a DW basis. They are observed in the post lens tear film as round, discrete deposits that vary in size and clarity.<sup>13, 20-22, 41, 42</sup> They may be scattered or clumped behind the lens and tend to appear as if stuck in the epithelium.<sup>21</sup> The looser the lens fit, the higher the number of mucin balls seen.<sup>20</sup> They do not appear to cause any symptoms such as reduction in vision or discomfort and do not have any consequence with regard to ocular health. Removal of the lens and subsequent blinking removes the mucin balls and leaves indentations in the epithelial surface. These pits rapidly fill with tear fluid and if fluorescein is introduced, the pits appear to “stain” markedly, although there is no actual compromise to the corneal epithelium, but rather the fluorescein is “pooling” in the epithelial indentations.<sup>13, 43</sup> The composition of mucin balls is primarily mucin with some tear proteins and a little lipid.<sup>23</sup> Their production is thought to arise as a result of the relationship between the back surface of the lens and the tear film, whereby a shearing force effectively ‘rolls up’ the tear mucus into balls.<sup>13, 20, 42</sup> The higher modulus of SiH lenses undoubtedly contributes to this mechanism,<sup>42</sup> although the composition of the surface treatment may also have an effect.

### Figure 4: Conjunctival epithelial flaps can be seen with continuous wear

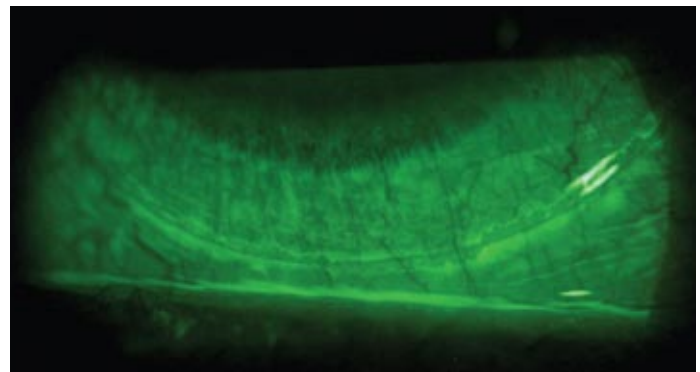


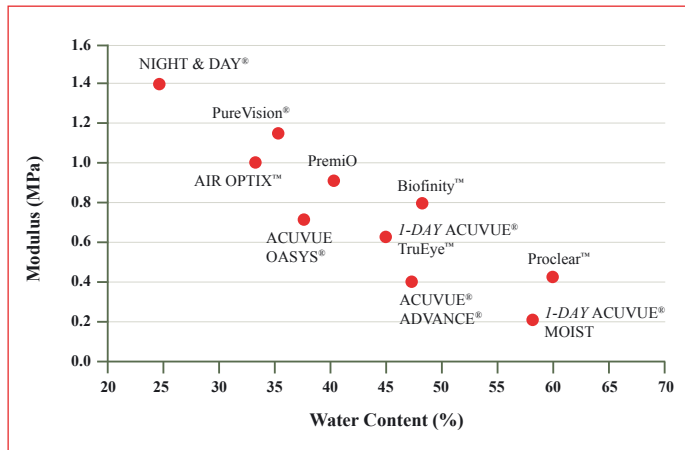
Image courtesy of Tom Løfstrøm, Private Practitioner, Denmark.

### Conjunctival epithelial flaps (CEFs)

This phenomenon was first reported in 2005 in patients wearing SiH lenses on a CW basis<sup>44</sup> and is best observed following the instillation of fluorescein, as the fluorescein pools underneath the flap (*Figure 4*). CEFs represent either a splitting of the conjunctival epithelium from underlying tissue or a “ruffling” of loose conjunctival tissue over the edge of the lens. They are usually found approximately 0.5-1mm away from the edge of the lens in the superior or inferior quadrants and mark the limit of vertical lens movement. The appearance of CEFs varies with lens modality, with small flaps ranging from 0.1 to 0.5mm in DW, to larger in CW (up to 9mm). The rate of occurrence is reported as 3% in DW and 37% in CW.<sup>44</sup> The aetiology of CEFs is likely to be mechanical and is possibly related to lens modulus and edge profile or edge shape. A recently published study found CEFs occurred more commonly in wearers of lotrafilcon A, which reportedly has a less rounded edge profile in comparison with balafilcon A.<sup>45</sup> Although patients exhibiting CEFs are usually asymptomatic and the condition appears to be benign, any potential long-term effects are not yet fully understood.

As reported above, mechanical complications can occur with relatively stiff hydrogel materials. Modulus is closely linked to water content<sup>1</sup> and the amount of siloxane groups incorporated, as is seen in *Figure 5*. Those materials with a higher oxygen permeability (Dk) due to increased amounts of siloxane groups being incorporated, generally tend to have higher moduli. More recent SiH materials have been formulated with DW in mind, looking for a balance between oxygen delivery and other important features to improve patient comfort. A reduction in the relative silicone content results in a lens with a higher water content and hence a lower modulus, thus reducing the potential chance of inducing mechanical complications.

**Figure 5: Elastic modulus vs. water content for silicone hydrogel lenses\***



\*Values stated are manufacturers' stated values and have been obtained using non-standardised methods.

### Lens deposition

Several studies have been carried out looking at the type and quantity of deposition associated with SiH lenses.<sup>46-55</sup> SiH lenses deposit significantly lower levels of protein than conventional hydrogel materials, especially group IV ionic materials.<sup>47, 50, 52</sup> Whilst only a small amount of protein is deposited on the surface of SiH materials, it has been shown that a high proportion of the protein is inactive or denatured, particularly on surface treated materials.<sup>52</sup> This is important because not only is denatured protein harder to remove from the lens surface, it has also been implicated in triggering the immune response that can cause contact lens papillary conjunctivitis (CLPC).<sup>56-58</sup>

Lipid deposition on SiHs can be a significant problem.<sup>48,55</sup> Some SiH wearers accumulate high levels of lipid deposit over several days that can hinder vision. These deposits show a characteristic haze and lipid globules on the lens surface (*Figure 6*). It is generally accepted that the most efficient way of managing lens deposits, especially with SiH materials, is to recommend to all lens wearers that they carry out a rub and rinse step during the cleaning process.<sup>48,59</sup> Evidence suggests that deposition can be significantly reduced, if not eliminated completely, by the simple incorporation of a digital rub step, with either multipurpose or peroxide based solutions, into the care regime.<sup>59</sup> For the small proportion of patients where deposition remains an issue, causing a reduction in comfort or vision, they may benefit from replacing their lenses every two weeks rather than every four.<sup>50, 55, 60, 61</sup> The use of additional surfactant cleaners containing alcohol, such as Miraflow, will also help in deposit removal.<sup>48</sup> Finally, patients with meibomian gland dysfunction often have more significant problems with lipid deposition and it is important to initiate appropriate lid hygiene measures in patients who exhibit obvious lid margin disease.<sup>62</sup>

**Figure 6: Poorly wetting silicone hydrogel material surface with characteristic haze and lipid globules**

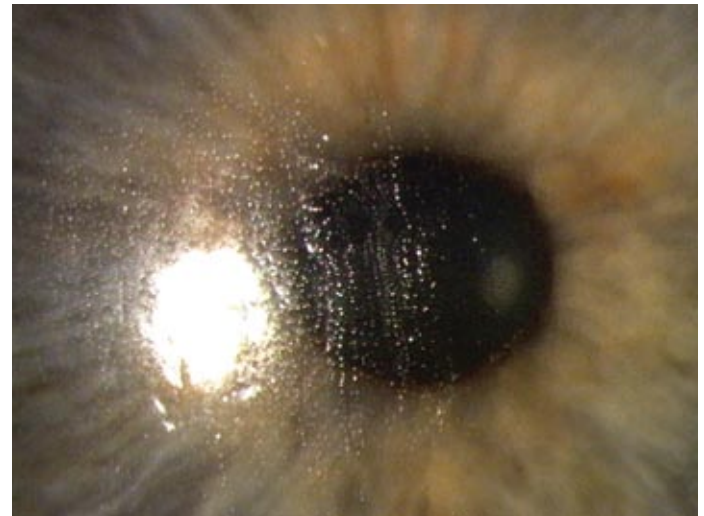


Image courtesy of Brian Tompkins, Private Practitioner, Northampton, UK.

### Lens/solution compatibility

Anecdotal and published reports of corneal staining associated with certain SiH lens and solution combinations has led to much interest and ongoing research.<sup>63-77</sup> Reported cases suggest that the solution induced staining observed is either diffuse punctate staining across the whole cornea, or staining in a ring around the corneal periphery (*Figure 7*).<sup>78</sup> Andrasko and Ryen have carried out studies looking at many different lens/solution combinations, in an attempt to quantify the associated levels of staining observed.<sup>72, 79</sup> They examined the type (severity) of staining in each of five regions of the cornea after 2 and 4 hours of lens wear for each lens/solution combination examined

**Figure 7: Solution induced corneal staining seen with some lens and multipurpose solution combinations**

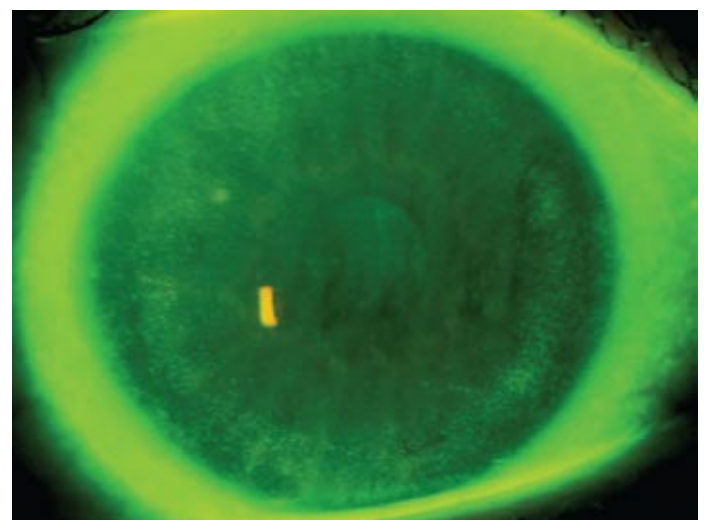


Image courtesy of Kathy Dumbleton, Centre for Contact Lens Research, University of Waterloo, Canada.

and used these results to obtain an average staining percentage. They suggest that staining is more significant with certain combinations. Overall, comfilcon A and senofilcon A showed the lowest percentage areas of solution-induced corneal staining with the care regimens tested and all of the SiH lenses tested showed lower levels of staining with the hydrogen peroxide based solution than with multipurpose solutions.

The Institute for Eye Research (IER) in Australia have carried out similar work and produced the “IER Matrix”<sup>80, 81</sup> although their study differed somewhat in design.<sup>80</sup> Rather than examining the eye for staining after two hours of lens wear, the patients in the IER study wore lenses for three months, using the specified care system. In total, 20 SiH lens/solution combinations were examined. The IER matrix shows the percentage of patients per month who had solution induced corneal staining during the first three months of wear in a particular combination. Whilst the study finds differing results in terms of the combinations, the study seems to be in agreement with the Andrasko studies, in that the lowest rates and percentages of staining are seen with hydrogen peroxide-based solutions.

Many practitioners are now aware of potential lens/solution compatibility issues, but what is the clinical implication of this micro-punctate staining seen in certain SiH wearers? Andrasko states that wearers who experience solution related corneal staining are likely to also report slightly lower subjective comfort.<sup>72,79</sup> However, it has been shown by others that there is no apparent strong correlation between symptoms and the degree of staining observed, and that patients who exhibit solution based staining are largely asymptomatic.<sup>63,64</sup> In addition, a retrospective analysis of patient records showed that wearers who show low grade punctate epithelial staining are three times more likely to experience a corneal infiltrative event (CIE) and the rate of CIEs increased as the rate of staining increased for specific lens/solution combinations.<sup>73</sup> In this study, peroxide-based solutions consistently resulted in lower levels of staining and sterile infiltrates.

There is absolutely no evidence to suggest that solution-induced corneal staining predisposes a patient to a more sinister event such as microbial keratitis.<sup>76, 82, 83</sup> However, recent evidence that solution-induced corneal staining can have a significant detrimental effect on epithelial barrier function<sup>84</sup> would also suggest that avoidance of excessive degrees of solution-induced corneal staining is advisable.

It would appear that the optimum time to observe corneal staining in SiH wearers is 2 to 4 hours after lens insertion.<sup>63</sup> With this in mind, it is useful to schedule a follow-up visit to fall within this time-frame, especially if there are comfort issues in an otherwise well-fitting lens. Bearing in mind that solution-induced corneal staining is often asymptomatic, it is important to use fluorescein at all aftercare visits and all staining is best seen with the aid of a yellow barrier filter.<sup>85</sup> Due to the potential issues discussed above, it is also important to make sure you know what solution your patient is using, and that when prescribing CLs the most appropriate solution for the particular lens type should also be prescribed and specified on the written prescription. Should clinically significant staining be observed, then consider an alternative care regimen.

### **Inflammatory and infective complications**

Despite the significant advantages of these novel materials with regards to their oxygen performance, complications are still reported with SiHs, particularly when used for overnight wear (ON). Numerous studies have been carried out looking at the rates of inflammation and infection associated with SiH materials, particularly when used in a continuous wear (CW) modality. In any epidemiological research, the definitions used for the test condition can have a powerful effect on any estimate of incidence or prevalence. It is therefore difficult to report accurately any incidence rates for inflammatory events, as the results will depend on the study design and criteria used for reporting infiltrates. Szczotka-Flynn and co-workers carried out a meta-analysis of published studies of the risks of CIEs associated with SiH CW compared with low Dk hydrogel extended wear (EW).<sup>86</sup> They found that using a definition of ‘the absence or presence of any grade of infiltrate’ suggested an approximate doubling of the risk of a CIE with 30 nights CW of SiH materials as compared with 6 nights EW of low Dk hydrogel (i.e. non silicone-based) lenses. However, they also concluded that a 30 day wear schedule may be more of a risk factor than the SiH material itself. A recent presentation of Szczotka-Flynn’s work<sup>87</sup> concluded that the data supporting the risks of CIEs associated with 30 nights CW were fairly consistent, with 3-4% eyes per year suffering a CIE in association with 30 night SiH CW, as compared with 1-2% eyes per year for 6 night hydrogel EW. This would suggest that practitioners recommending SiH lenses for CW may be better to consider a 6 night EW replacement schedule rather than a 30 night replacement schedule. However, previous work investigating this factor with one material alone showed that the risks associated with 30 night CW were no worse than 6 night EW removal.<sup>88, 89</sup>

Historically, overnight wear and length of overnight wear are strongly correlated with increased risks of inflammatory and infective complications.<sup>90</sup> However, other risk factors (modifiable and non-modifiable) have also been identified by various authors,<sup>91-94</sup> and these are summarised in *Table 1*.

**Table 1: Modifiable and non-modifiable risk factors for microbial keratitis for contemporary contact lens types<sup>91,94</sup>**

Modifiable factors
Overnight wear
>6 nights overnight wear
Use while on holidays
Swimming without goggles/disinfection
Hand-washing
Low hygiene
Poor case hygiene
Internet purchase
Poor health
Smoking
Non-modifiable factors
<6 months in extended wear
Male gender
Wearing lenses during winter months
High socioeconomic status
Young age

The generally accepted figure for the annualised incidence of microbial keratitis (MK) in conventional hydrogel DW patients is 4 per 10,000 wearers,<sup>90,95-97</sup> and EW has been reported to increase this risk by approximately five times.<sup>90,95-97</sup> Although it was initially hoped that the risk for MK would be lower with SiH materials,<sup>98</sup> study results now indicate that the risk is similar to that found with conventional hydrogel materials for both DW and CW.<sup>91,97,99-101</sup> Despite the similar incidence of MK for both conventional and SiH lenses, studies do suggest that the severity of the condition and disease duration are reduced with CW or EW SiH materials.<sup>99,102</sup>

One factor that may have some relevance to MK and inflammatory responses relates to binding of pathogenic organisms to the lens material. Several studies have looked

at the in-vitro binding of bacteria and Acanthamoeba to SiH surfaces. Some SiHs have been shown to exhibit higher levels of bacterial adhesion to the lens surfaces than conventional hydrogels.<sup>103,104</sup> This has been related not only to the increased surface hydrophobicity of these materials, but also their increased oxygen transmissibility, which directly promotes bacterial binding and biofilm formation.<sup>104</sup> Some SiHs have also been shown to have significantly higher levels of Acanthamoeba attachment to the lens surface than conventional hydrogels,<sup>105-107</sup> which has also been attributed to the increased hydrophobicity of the SiH materials. Acanthamoeba attachment has been shown to be affected by SiH material type, with a significantly greater affinity for the first generation lotrafilcon A compared with second generation galyfilcon A and the hydrogel material etafilcon A, even in the presence of a bacterial biofilm.<sup>107</sup> However, these studies point out that these results are purely in-vitro findings, and the benefit of increased oxygen transmission offered by SiH materials may reduce the likelihood of an environment where the corneal epithelium is more susceptible to bacterial invasion and keratitis. Bearing in mind the increased propensity for bacterial and Acanthamoeba attachment to these materials, it is important that wearers are advised of the risks of wearing SiHs in environments where they are more likely to be exposed to sources of these organisms, such as swimming pools and hot tubs.

### Therapeutic indications

SiHs are finding an increasing role in hospital practice and for therapeutic applications.<sup>108-118</sup> Many therapeutic lenses are worn overnight to provide continuous pain relief and healing of ocular surface disorders. Overnight wear can also be useful if the insertion and removal process is likely to be associated with pain, trauma to the epithelium or increased risk of infection. SiH materials offer obvious benefits in terms of increased oxygen transmissibility. This will not only reduce the risk of hypoxic compromise to the cornea compared to hydrogels, but the extra oxygen is desirable for healing and repair. Several studies have been carried out showing that the therapeutic use of SiHs for the management of ocular surface disorders are safe and effective, in both adults and children.<sup>108-118</sup>

Currently lotrafilcon A, balafilcon A and senofilcon A all have FDA and European approval for use as therapeutic lenses for a range of acute and chronic conditions. Tailor-made SiHs are also available for use in hospitals (such as the Definitive material from Ultravision), including aphakic and bandage lenses, lenses for high myopia, paediatric lenses and those that can be tinted with cosmetic or prosthetic tints. The Kerasoft lens for keratoconus is also available in the Definitive material.

## How has contact lens practice changed since the introduction of SiH materials?

In 2003, SiH lenses represented only 3% of the contact lens market, according to figures from the ACLM.<sup>119</sup> This represented a 32% increase from 2002, but was still a relatively low proportion of the lens market in comparison with traditional hydrogel disposable lenses, which accounted for 45%. More recent figures from the ACLM for 2007 suggest that demand for SiH lenses continues to grow, showing a 20% increase on 2006 figures. In 2007, SiH materials represented 21% of the lens market, overtaking traditional disposable hydrogels at 16%. However, daily disposables continue to hold the greatest share of the market, with 55% market share.

With respect to practitioner behaviour in prescribing contact lenses, the latest UK figures for 2008<sup>120</sup> suggest that 32% of new fits are in SiH materials, as are 41% of refits. This is similar to 2007 figures,<sup>121</sup> but is a significant increase from 2004, when SiH materials accounted for only 6% of new fits and 16% of refits.<sup>122</sup>

First generation SiH lenses were originally marketed for CW, and SiH materials account for 96% of all CW fits. However, the CW modality has remained relatively constant since the introduction of these lenses, representing 7% of new fits and 13% of refits.<sup>120</sup> These data show the rapid rise in popularity of SiH lenses for DW and/or occasional overnight wear, as both practitioners and patients understand and appreciate the benefits of such materials for corneal health and comfort.

The practitioner wishing to fit SiH materials as their first choice has, in the past, been limited by the range of materials, prescriptions and fitting parameters. However, the majority of wearers can now be fitted with SiHs and there is a wide range of lenses and parameters to choose from, with a choice of torics, multifocals and made-to-order lathe cut lenses available in higher prescriptions.

## New developments

The original drive for the development of SiH materials was the maximisation of oxygen transmission to allow the possibility of overnight wear without hypoxic complications. Since their introduction in the late 1990's, many changes have taken place in the design of SiHs. It has become apparent that as well as the desire for lens materials offering optimum health benefits, comfort and convenience remain key to growth in the contact lens market.

With the vast majority of wearers still concerned about comfort and reduced wearing time, much research and development continues to optimise the parameters that lead to increased comfort. Two new SiH lenses have recently been launched which aim to address this situation, with the addition of wetting agents and increasing replacement frequency. Air Optix Aqua from CIBA Vision employs a plasma coating and hydrophilic moisture agent that is said to bind to the lens surface and claimed to enhance comfort on insertion. The material is lotrafilcon B, but is reported to have a lower initial contact angle than the original material<sup>123</sup> and increased deposit resistance. Avaira from CooperVision (enfilcon A, recently launched in the US as a two-weekly replacement, DW, SiH lens) employs similar technology to that used in comfilcon A, reducing the need for surface treatment to ensure wettability and low modulus. It also features aspheric optics and a UV inhibitor.

Efforts have been made to arrive at a manufacturing process that offers a financially viable method for producing the ultimate in convenience and health benefits, which would be a SiH daily disposable lens. It can be a dilemma for practitioners recommending contact lens products, when they have to balance the oxygen performance benefits of a frequent replacement SiH lens against the convenience and flexibility of a daily disposable lens. The world's first SiH daily disposable, *I-DAY* ACUVUE® TruEye™, is now available in the UK, having first been introduced by Johnson & Johnson Visioncare earlier this year at the BCLA conference. The lens is manufactured from a new material, narafilcon A and features HYDRACLEAR® 1, a unique technology that embeds a moisture-rich ingredient specifically designed for this daily disposable modality.<sup>124</sup> The technology is a new formulation of similar technology used in ACUVUE® ADVANCE™ and ACUVUE OASYS®, yet optimised for the production of daily disposable lenses.

According to the latest prescribing figures, this year was the first year that daily disposable lenses were recorded as being the most popular modality for new fits in the UK, with 46% of new fits.<sup>120</sup> Given that SiH materials represent 32% of the monthly and 1-2 weekly replacement modalities, it is not unreasonable to suggest that practitioners will be very interested in having a daily disposable SiH to offer the benefits of both optimal health and optimum convenience to their patients.

## Summary

In the last decade since SiH materials first appeared, there have been approximately 250 peer-reviewed papers in scientific journals and many more non peer-reviewed articles and posters at conferences, supporting the claims of superior performance in terms of corneal health and patient comfort. Although overnight wear of these materials continues to occupy only a small share of the proportion of CL fits, the enhancement of SiH material properties with a view to DW has led to a year-on-year increase in their prescribing rate.<sup>122, 125-127</sup> It seems likely that SiH materials will continue to occupy a significant proportion of the disposable lens market and, with a daily disposable SiH now a commercial reality, with more surely to follow, the popularity of this family of materials will undoubtedly continue to rise. Perhaps the one disappointment of SiH materials is that the risk of MK and rate of corneal inflammatory complications with ON wear does not appear to have reduced with increased oxygen performance; this will surely be a major factor in the drive to further enhance the materials used for future generation lenses. Changing lens characteristics to encourage better tear exchange or creating lenses with inherent anti-microbial surfaces or surface coatings<sup>128-130</sup> may lead to lower risks of infection associated with ON wear.

When selecting a SiH lens for patients there are many factors to consider. Balancing the material properties for best performance involves consideration of the design, oxygen transmissibility, mechanical properties, water content and surface wettability. It is always worth remembering that patient satisfaction is primarily driven by comfort and vision, and increasing comfort, in addition to eliminating hypoxia and minimising adverse effects, should be the aim of every practitioner in their strive for enhanced patient comfort and reduced patient drop-out.

## About the authors

Dr Karen French Phd MCOptom is an independent optometrist who works in private and hospital practice in Cambridgeshire. Professor Lyndon Jones Phd FCOptom, DipCLP, DipOrth FAAO (DipCh) FIACLE works at the School of Optometry and is Associate Director of the Centre for Contact Lens Research in Waterloo, Canada.

## Acknowledgment

This article was originally published in *Optometry Today* 2008 48:18 38-43.

## References

1. Jones L, Subbaraman LN, et al.: Surface treatment, wetting and modulus of silicone hydrogels. *Optician* 2006; 232;6067: 28 - 34.
2. Jones L, Dumbleton K: Soft lens extended wear and complications. in *Manual of Contact Lens Prescribing and Fitting*, 2nd. M.M. Hom and A. Bruce, Editors. Oxford, Butterworth-Heinemann, 2006, p 393 - 441.
3. Tighe B: Silicone hydrogels: Structure, properties and behaviour. in *Silicone Hydrogels: Continuous Wear Contact Lenses*, 2nd. D. Sweeney, Editor. Oxford, Butterworth-Heinemann, 2004, p 1 - 27.
4. Tighe B: Contact Lens Materials. in *Contact Lenses*, 5th. A. Phillips and L. Speedwell, Editors. Edinburgh, Butterworth-Heinemann, 2006, p 59 - 78.
5. Jones L, Dumbleton K: Silicone hydrogels part I: Technological developments. *Optometry Today* 2005; Nov 18th 23 - 29.
6. Jones L, Dumbleton K: Silicone hydrogel lenses: Fitting procedures and in-practice protocols for continuous wear lenses. *Optician* 2002; 223;5840: 37 - 45.
7. Dumbleton KA, Chalmers RL, et al.: Effect of lens base curve on subjective comfort and assessment of fit with silicone hydrogel continuous wear contact lenses. *Optom Vis Sci* 2002; 79;10: 633 - 637.
8. Dumbleton KA, Jones L: Silicone hydrogel lenses: Material properties and patient selection. *Optician* 2002; 223;5836: 16 - 22.
9. Dumbleton KA, Jones L: Silicone hydrogel lenses: Follow-up and management. *Optician* 2002; 223;5845: 34 - 43.
10. Jones L, Dumbleton K: Soft contact lens fitting. in *Contact Lenses*, 5th. A. Phillips and L. Speedwell, Editors. Edinburgh, Butterworth-Heinemann, 2006, p 223 - 240.
11. Sweeney D, du Toit R, et al.: Clinical performance of silicone hydrogel lenses. in *Silicone hydrogels: Continuous wear contact lenses*, 2nd. D. Sweeney, Editor. Oxford, Butterworth-Heinemann, 2004, p 164 - 216.
12. Dumbleton K: Adverse events with silicone hydrogel continuous wear. *Cont Lens Anterior Eye* 2002; 25;3: 137-146.
13. Dumbleton K: Noninflammatory silicone hydrogel contact lens complications. *Eye Contact Lens* 2003; 29;1 Suppl: S186-189; discussion S190-181, S192-184.
14. Stapleton F, Stretton S, et al.: Silicone hydrogel contact lenses and the ocular surface. *Ocul Surf* 2006; 4;1: 24-43.
15. Holden BA, Stephenson A, et al.: Superior epithelial arcuate lesions with soft contact lens wear. *Optom Vis Sci* 2001; 78;1: 9-12.
16. Jalbert I, Sweeney DF, et al.: Epithelial split associated with wear of a silicone hydrogel contact lens. *CLAO J* 2001; 27;4: 231-233.
17. Skotnitsky C, Sankaridurg PR, et al.: General and local contact lens induced papillary conjunctivitis (CLPC). *Clin Exp Optom* 2002; 85;3: 193-197.
18. Maldonado-Codina C, Morgan PB, et al.: Comparative clinical performance of rigid versus soft hyper Dk contact lenses used for continuous wear. *Optom Vis Sci* 2005; 82;6: 536-548.
19. Skotnitsky CC, Naduvilath TJ, et al.: Two presentations of contact lens-induced papillary conjunctivitis (CLPC) in hydrogel lens wear: local and general. *Optom Vis Sci* 2006; 83;1: 27-36.
20. Dumbleton K, Jones L, et al.: Clinical characterization of spherical post-lens debris associated with lotrafilcon high-Dk silicone lenses. *CLAO J* 2000; 26;4: 186-192.
21. Pritchard N, Jones L, et al.: Epithelial inclusions in association with mucin ball development in high-oxygen permeability hydrogel lenses. *Optom Vis Sci* 2000; 77;2: 68-72.
22. Craig JP, Sherwin T, et al.: An evaluation of mucin balls associated with high-DK silicone-hydrogel contact lens wear. *Adv Exp Med Biol* 2002; 506;Pt B: 917-923.
23. Millar TJ, Papas EB, et al.: Clinical appearance and microscopic analysis of mucin balls associated with contact lens wear. *Cornea* 2003; 22;8: 740-745.
24. Young G, Mirejovsky D: A hypothesis for the aetiology of soft contact lens-induced superior arcuate keratopathy. *Int Contact Lens Clin* 1993; 20;9/10: 177 - 179.
25. Hine N, Back A, et al.: Aetiology of arcuate epithelial lesions induced by hydrogels. *J Brit Contact Lens Assoc* 1987; *Trans Ann Clin Conf*: 48-50.
26. Malinovsky V, Pole J, et al.: Epithelial splits of the superior cornea in hydrogel contact lens patients. *Int Contact Lens Clin* 1989; 16;9&10: 252-254.
27. O'Hare N, Naduvilath T, et al.: Superior epithelial arcuate lesions (SEALs): A case control study. *Invest Ophthalmol Vis Sci* 2000; 41;4: s386.
28. Jones L, Jones D: Superior epithelial arcuate lesions. *Optician* 1995; 209;5500: 32-33.
29. O'Hare N, Stapleton F, et al.: Interaction between the contact lens and the ocular surface in the etiology of superior epithelial arcuate lesions. *Adv Exp Med Biol* 2002; 506;Pt B: 973-980.



30. Holden B, Sankaridurg P, et al.: Adverse events and infections: Which ones and how many ? in *Silicone Hydrogels: The Rebirth of Continuous Wear Contact Lenses*, D. Sweeney, Editor. Oxford, Butterworth-Heinemann, 2000, p 150 - 213.
31. O'Hare N, Naduvilath T, et al.: A clinical comparison of limbal and paralimbal superior epithelial arcuate lesions (SEALs) in high Dk EW. *Invest Ophthalmol Vis Sci* 2001; 42:4: s595.
32. Allansmith MR, Korb DR, et al.: Giant papillary conjunctivitis in contact lens wearers. *Am J Ophthalmol* 1977; 83:5: 697-708.
33. Sugar A, Meyer RF: Giant papillary conjunctivitis after keratoplasty. *Am J Ophthalmol* 1981; 91:2: 239-242.
34. Barishak Y, Zavaro A, et al.: An immunological study of papillary conjunctivitis due to contact lenses. *Curr Eye Res* 1984; 3:10: 1161-1168.
35. Dart J: Contact lens associated giant papillary conjunctivitis. *Contax* 1986; November: 6-22.
36. Allansmith MR, Ross RN: Giant papillary conjunctivitis. *Int Ophthalmol Clin* 1988; 28:4: 309-316.
37. Donshik PC: Contact lens chemistry and giant papillary conjunctivitis. *Eye Contact Lens* 2003; 29:1 Suppl: S37-39; discussion S57-39, S192-194.
38. Donshik P, Long B, et al.: Inflammatory and mechanical complications associated with 3 years of up to 30 nights of continuous wear of lotrafilcon A silicone hydrogel lenses. *Eye Contact Lens* 2007; 33:4: 191-195.
39. McNally J, McKenney CD: A clinical look at a silicone hydrogel extended wear lens. *Contact Lens Spectrum* 2002; 17:1: 38 - 41.
40. Stern J, Skotnitsky C, et al.: Comparison of the incidence of contact lens papillary conjunctivitis (CLPC) between six and thirty night high Dk soft extended wear schedules. *Invest Ophthalmol Vis Sci* 2001; 42:4: s597.
41. Tan J, Keay L, et al.: Tear microspheres (TMSS) with high Dk lenses. *Optom Vis Sci* 1999; 76:12s: 226.
42. Tan J, Keay L, et al.: Mucin balls with wear of conventional and silicone hydrogel contact lenses. *Optom Vis Sci* 2003; 80:4: 291-297.
43. Ladage PM, Petroll WM, et al.: Spherical indentations of human and rabbit corneal epithelium following extended contact lens wear. *CLAO J* 2002; 28:4: 177-180.
44. Lofstrom T, Kruse A: A conjunctival response to silicone hydrogel lens wear. *Contact Lens Spectrum* 2005; 20:9: 42 - 44.
45. Santodomingo-Rubido J, Wolffsohn J, et al.: Conjunctival epithelial flaps with 18 months of silicone hydrogel contact lens wear. *Eye Contact Lens* 2008; 34:1: 35-38.
46. Jones L, Senchyna M, et al.: Lysozyme and lipid deposition on silicone hydrogel contact lens materials. *Eye Contact Lens* 2003; 29:1 Suppl: S75-S79.
47. Senchyna M, Jones L, et al.: Quantitative and conformational characterization of lysozyme deposited on balafilcon and etafilcon contact lens materials. *Curr Eye Res* 2004; 28:1: 25-36.
48. Ghormley N, Jones L: Managing lipid deposition on silicone hydrogel lenses. *Contact Lens Spectrum* 2006; 21:1: 21.
49. Subbaraman LN, Bayer S, et al.: Rewetting drops containing surface active agents improve the clinical performance of silicone hydrogel contact lenses. *Optom Vis Sci* 2006; 83:3: 143 -151.
50. Subbaraman LN, Glasier MA, et al.: Kinetics of in vitro lysozyme deposition on silicone hydrogel, PMMA, and FDA groups I, II, and IV contact lens materials. *Curr Eye Res* 2006; 31:10: 787-796.
51. Subbaraman LN, Jones L: Activity of lysozyme deposited on conventional and silicone hydrogel contact lenses as a function of time. *Invest Ophthalmol Vis Sci* 2007; ARVO abstracts;E-abstract 5393.
52. Suwala M, Glasier MA, et al.: Quantity and conformation of lysozyme deposited on conventional and silicone hydrogel contact lens materials using an in vitro model. *Eye Contact Lens* 2007; 33:3: 138-143.
53. Chow L, Subbaraman LN, et al.: Kinetics of in vitro lactoferrin deposition on silicone hydrogel and FDA group II and group IV hydrogel contact lens materials. *J Biomat Sci Polym Ed* 2008; In press.
54. Glasier MA, Keech A, et al.: Conformational and quantitative characterization of lysozyme extracted from galyfilcon and senofilcon silicone hydrogel contact lenses. *Curr Eye Res* 2008; 33:1: 1-11.
55. Carney FP, Nash WL, et al.: The adsorption of major tear film lipids in vitro to various silicone hydrogels over time. *Invest Ophthalmol Vis Sci* 2008; 49:1: 120-124.
56. Fowler SA, Allansmith MR: Evolution of soft contact lens coatings. *Arch Ophthalmol* 1980; 98:1: 95-99.
57. Allansmith MR: Immunologic effects of extended-wear contact lenses. *Ann Ophthalmol* 1989; 21:12: 465-467, 474.
58. Allansmith MR: Giant papillary conjunctivitis. *J Am Optom Assoc* 1990; 61:6 Suppl: S42-46.
59. Nichols JJ: Deposition rates and lens care influence on galyfilcon A silicone hydrogel lenses. *Optom Vis Sci* 2006; 83:10: 751-757.
60. Jones L, Evans K, et al.: Lipid and protein deposition of N-vinyl pyrrolidone-containing group II and group IV frequent replacement contact lenses. *CLAO J* 1997; 23:2: 122-126.
61. Jones L, Mann A, et al.: An in vivo comparison of the kinetics of protein and lipid deposition on group II and group IV frequent-replacement contact lenses. *Optom Vis Sci* 2000; 77:10: 503-510.
62. Sindt CW, Longmuir RA: Contact lens strategies for the patient with dry eye. *Ocul Surf* 2007; 5:4: 294-307.
63. Garofalo RJ, Dassanayake N, et al.: Corneal staining and subjective symptoms with multipurpose solutions as a function of time. *Eye Contact Lens* 2005; 31:4: 166 - 174.
64. Jones L, MacDougall N, et al.: Asymptomatic corneal staining associated with the use of balafilcon silicone-hydrogel contact lenses disinfected with a polyaminopropyl biguanide-preserved care regimen. *Optom Vis Sci* 2002; 79:12: 753-761.
65. Papas EB, Carnt N, et al.: Complications associated with care product use during silicone daily wear of hydrogel contact lens. *Eye Contact Lens* 2007; 33:6 Pt 2: 392-393; discussion 399-400.
66. Epstein A: SPK with daily wear of silicone hydrogel lenses and MPS. *Contact Lens Spectrum* 2002; 17:11: 30.
67. Fonn D: Observations of corneal staining with MPS and silicone hydrogel lenses. *Contact Lens Spectrum* 2002; 17:11: 32.
68. Levy B: Contact lens and solution manufacturer responds with data. *Contact Lens Spectrum* 2002; 17:11: 34.
69. Amos C: Performance of a new multipurpose solution used with silicone hydrogels. *Optician* 2004; 227:5945: 18-22.
70. Amos C: A clinical comparison of two soft lens care systems used with silicone hydrogel contact lenses. *Optician* 2004; 227:5933: 16 - 20.
71. Dumbleton K, Keir N, et al.: Objective and subjective responses in patients refitted to daily-wear silicone hydrogel contact lenses. *Optom Vis Sci* 2006; 83:10: 758-768.
72. Andrasko G, Ryen K: A series of evaluations of MPS and silicone hydrogel lens combinations. *Rev Cornea and Contact Lenses* 2007; March: 36 - 42.
73. Carnt N, Jalbert I, et al.: Solution toxicity in soft contact lens daily wear is associated with corneal inflammation. *Optom Vis Sci* 2007; 84:4: 309-315.
74. Santodomingo-Rubido J: The comparative clinical performance of a new polyhexamethylene biguanide- vs a polyquad-based contact lens care regime with two silicone hydrogel contact lenses. *Ophthalmic Physiol Opt* 2007; 27:2: 168-173.
75. Zigler L, Cedrone R, et al.: Clinical evaluation of silicone hydrogel lens wear with a new multipurpose disinfection care product. *Eye Contact Lens* 2007; 33:5: 236-243.
76. Levy B, Orsborn G: Clinical risks: Myths and truths. *Contact Lens Spectrum* 2008; 23:1: 42 - 46.
77. Paugh JR, Marsden HJ, et al.: A pre-application drop containing carboxymethylcellulose can reduce multipurpose solution-induced corneal staining. *Optom Vis Sci* 2007; 84:1: 65-71.
78. Jones L: Understanding incompatibilities. *Contact Lens Spectrum* 2004; 19:7 (suppl): 4 - 7.
79. Andrasko G, Ryen K: Corneal staining and comfort observed with traditional and silicone hydrogel lenses and multipurpose solution combinations. *Optometry* 2008; 79:8: 444-454.
80. Carnt N, Willcox M, et al.: Corneal staining: The IER matrix study. *Contact Lens Spectrum* 2007; 22:9: 38 - 43.
81. Carnt N, Evans V, et al.: IER matrix update: adding another silicone hydrogel. *Contact Lens Spectrum* 2008; 23:3: 28 - 35.
82. Ward KW: Superficial punctate fluorescein staining of the ocular surface. *Optom Vis Sci* 2008; 85:1: 8-16.
83. Sweeney DF, Naduvilath TJ: Are inflammatory events a marker for an increased risk of microbial keratitis? *Eye Contact Lens* 2007; 33:6 Pt 2: 383-387; discussion 399-400.
84. Hall J, Paugh J, et al.: A pilot study of the effect of silicone-hydrogel lenses and marketed multipurpose solutions on human epithelial barrier function. *Invest Ophthalmol Vis Sci* 2007; 47;ARVO abstracts: E-abstract 5400.

85. Cox I, Fonn D: Interference filters to eliminate the surface reflex and improve contrast during fluorescein photography. *Int Contact Lens Clin* 1991; 18;9/10: 178-181.
86. Szczotka-Flynn L, Diaz M: Risk of corneal inflammatory events with silicone hydrogel and low dk hydrogel extended contact lens wear: a meta-analysis. *Optom Vis Sci* 2007; 84;4: 247-256.
87. Szczotka-Flynn L: It's all in the modality. BCLA Conference 2008;4.
88. Chalmers RL, McNally JJ, et al.: Risk factors for corneal infiltrates with continuous wear of contact lenses. *Optom Vis Sci* 2007; 84;7: 573-579.
89. Stern J, Wong R, et al.: Comparison of the performance of 6- or 30-night extended wear schedules with silicone hydrogel lenses over 3 years. *Optom Vis Sci* 2004; 81;6: 398-406.
90. Poggio EC, Glynn RJ, et al.: The incidence of ulcerative keratitis among users of daily-wear and extended-wear soft contact lenses. *N Engl J Med* 1989; 321;12: 779-783.
91. Stapleton F, Keay L, et al.: The incidence of contact lens-related microbial keratitis in Australia. *Ophthalmology* 2008; In press.
92. Dart JK, Radford CF, et al.: Risk factors for microbial keratitis with contemporary contact lenses: A case-control study. *Ophthalmology* 2008; In press.
93. Morgan PB, Efron N, et al.: Risk factors for the development of corneal infiltrative events associated with contact lens wear. *Invest Ophthalmol Vis Sci* 2005; 46;9: 3136-3143.
94. Stapleton F, Keay L, et al.: Risks of contact lens related microbial keratitis. *Optom Vis Sci* 2005; 82 E-abstract 050068.
95. Schein OD, Glynn RJ, et al.: The relative risk of ulcerative keratitis among users of daily-wear and extended-wear soft contact lenses. A case-control study. Microbial Keratitis Study Group. *N Engl J Med* 1989; 321;12: 773-778.
96. Cheng KH, Leung SL, et al.: Incidence of contact-lens-associated microbial keratitis and its related morbidity. *Lancet* 1999; 354;9174: 181-185.
97. Keay L, Stapleton F, et al.: Epidemiology of contact lens-related inflammation and microbial keratitis: a 20-year perspective. *Eye Contact Lens* 2007; 33;6 Pt 2: 346-353, discussion 362-343.
98. Holden BA, Sweeney DF, et al.: Microbial keratitis and vision loss with contact lenses. *Eye Contact Lens* 2003; 29;1 Suppl: S131-134; discussion S143-134, S192-134.
99. Schein OD, McNally JJ, et al.: The incidence of microbial keratitis among wearers of a 30-day silicone hydrogel extended-wear contact lens. *Ophthalmology* 2005; 112;12: 2172-2179.
100. Keay L, Edwards K, et al.: An early assessment of silicone hydrogel safety: pearls and pitfalls, and current status. *Eye Contact Lens* 2007; 33;6 Pt 2: 358-361.
101. Stapleton F, Keay L, et al.: The epidemiology of contact lens related infiltrates. *Optom Vis Sci* 2007; 84;4: 257-272.
102. Keay L, Edwards K, et al.: Factors affecting the morbidity of contact lens-related microbial keratitis: a population study. *Invest Ophthalmol Vis Sci* 2006; 47;10: 4302-4308.
103. Henriques M, Sousa C, et al.: Adhesion of *Pseudomonas aeruginosa* and *Staphylococcus epidermidis* to silicone-hydrogel contact lenses. *Optom Vis Sci* 2005; 82;6: 446-450.
104. Kodjikian L, Casoli-Bergeron E, et al.: Bacterial adhesion to conventional hydrogel and new silicone-hydrogel contact lens materials. *Graefes Arch Clin Exp Ophthalmol* 2008; 246;2: 267-273.
105. Beattie TK, Tomlinson A, et al.: Enhanced attachment of acanthamoeba to extended-wear silicone hydrogel contact lenses: a new risk factor for infection? *Ophthalmology* 2003; 110;4: 765-771.
106. Beattie TK, Tomlinson A, et al.: Surface treatment or material characteristic: the reason for the high level of Acanthamoeba attachment to silicone hydrogel contact lenses. *Eye Contact Lens* 2003; 29;1 Suppl: S40-43; discussion S57-49, S192-194.
107. Beattie TK, Tomlinson A, et al.: Attachment of Acanthamoeba to first- and second-generation silicone hydrogel contact lenses. *Ophthalmology* 2006; 113;1: 117-125.
108. Lim L, Tan DT, et al.: Therapeutic use of Bausch & Lomb PureVision contact lenses. *CLAO J* 2001; 27;4: 179-185.
109. Foulks GN, Harvey T, et al.: Therapeutic contact lenses: the role of high-Dk lenses. *Ophthalmol Clin North Am* 2003; 16;3: 455-461.
110. Kanpolat A, Ucakhan OO: Therapeutic use of Focus Night & Day contact lenses. *Cornea* 2003; 22;8: 726-734.
111. Montero J, Sparholt J, et al.: Retrospective case series of therapeutic applications of lotrafilcon a silicone hydrogel soft contact lenses. *Eye Contact Lens* 2003; 29;2: 72-75.
112. Rubinstein MP: Applications of contact lens devices in the management of corneal disease. *Eye* 2003; 17;8: 872-876.
113. Ambroziak AM, Szaflik JP, et al.: Therapeutic use of a silicone hydrogel contact lens in selected clinical cases. *Eye Contact Lens* 2004; 30;1: 63-67.
114. Mely R: Therapeutic and cosmetic indications of lotrafilcon a silicone hydrogel extended-wear lenses. *Ophthalmologica* 2004; 218 Suppl 1 29-38; discussion 45-26.
115. Ozkurt Y, Rodop O, et al.: Therapeutic applications of lotrafilcon a silicone hydrogel soft contact lenses. *Eye Contact Lens* 2005; 31;6: 268-269.
116. Bendoriene J, Vogt U: Therapeutic use of silicone hydrogel contact lenses in children. *Eye Contact Lens* 2006; 32;2: 104-108.
117. Engle AT, Laurent JM, et al.: Masked comparison of silicone hydrogel lotrafilcon A and etafilcon A extended-wear bandage contact lenses after photorefractive keratectomy. *J Cataract Refract Surg* 2005; 31;4: 681-686.
118. Lim N, Vogt U: Comparison of conventional and silicone hydrogel contact lenses for bullous keratoplasty. *Eye Contact Lens* 2006; 32;5: 250-253.
119. [www.aclm.org.uk](http://www.aclm.org.uk).
120. Morgan PB: Trends in UK contact lens prescribing 2008. *Optician* 2008; 235;6155: 18 - 19.
121. Morgan PB: Trends in UK contact lens prescribing 2007. *Optician* 2007; 234;6104: 16 - 17.
122. Morgan PB, Efron N: A decade of contact lens prescribing trends in the United Kingdom (1996-2005). *Cont Lens Anterior Eye* 2006; 29;2: 59 - 68.
123. Nash W, Sentell KB, et al.: The effect of surface modification on the in vitro contact angle of silicone hydrogel lenses. BCLA Poster 2008.
124. Jones L, Woods C: Compromises' end? The introduction of a silicone hydrogel daily disposable lens. Silicone Hydrogel Web-Site <http://www.siliconehydrogels.org/editorials/index.asp> 2008;June.
125. Woods CA, Jones DA, et al.: A seven year survey of the contact lens prescribing habits of Canadian optometrists. *Optom Vis Sci* 2007; 84;6: 505-510.
126. Woods CA, Morgan PB: Use of silicone hydrogel contact lenses by Australian optometrists. *Clin Exp Optom* 2004; 87;1: 19-23.
127. Morgan PB, Woods C, et al.: International contact lens prescribing in 2007. *Contact Lens Spectrum* 2008; 23;1: 36 - 41.
128. Danion A, Arsenault I, et al.: Antibacterial activity of contact lenses bearing surface-immobilized layers of intact liposomes loaded with levofloxacin. *J Pharm Sci* 2007.
129. Willcox MD: New strategies to prevent *Pseudomonas* keratitis. *Eye Contact Lens* 2007; 33;6 Pt 2: 401-403; discussion 410-401.
130. Zhu H, Kumar A, et al.: Fimbrilide-coated antimicrobial lenses: Their in vitro and in vivo effects. *Optom Vis Sci* 2008; 85;5: 292-300.